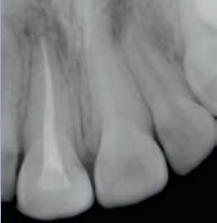


Septodont Case Studies *Collection*

Special Edition

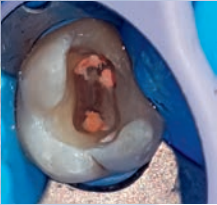
Acute Apical Periodontitis

Dr. Antonio Fernando Herrera de Luna



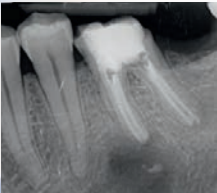
Maxillary Sinusitis of Endodontic Origin non-surgical management

P. Rebeca Mora Favela, I. Jiménez Bueno,
B. Itzel Jiménez Valdés



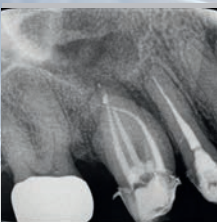Periapical healing: BioRoot™ RCS Bioactive potential

Dr. Rocco Zaccone, Dr Patrizio Galeano



Endodontic retreatment of an upper molar with periradicular perforation and lesion

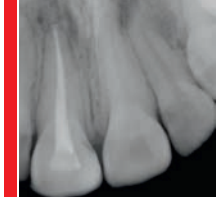Dr. Emanuele Ambu



Focus on: BioRoot™ RCS



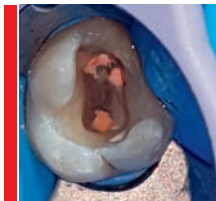
Content



Acute Apical Periodontitis of an upper right central incisor, obturated with BioRoot™ RCS

Dr. Antonio Fernando Herrera de Luna

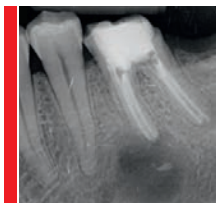
3



Maxillary Sinusitis of Endodontic Origin non-surgical management

P. Rebeca Mora Favela, I. Jiménez Bueno,
B. Itzel Jiménez Valdés

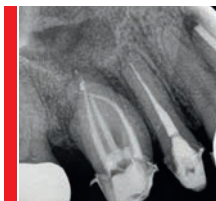
10



Periapical healing: BioRoot™ RCS Bioactive potential

Dr. Rocco Zaccone, Dr. Patrizio Galeano

15



Endodontic retreatment of an upper molar with periradicular perforation and lesion

Dr. Emanuele Ambu

19

Acute Apical Periodontitis of an upper right central incisor, obturated with BioRoot™ RCS

Author: Dr. Antonio Fernando Herrera de Luna

Practicing at a Specialized Endodontic Clinic since April 1989.

Research professor in the Endodontics department at Valle de México University's Reynosa campus from 2000 to 2017; professor of theory and clinical work in the Endodontics postgraduate program at UANL from 2009 to 2015.

Summary

Introduction: 18-year-old female patient with a history of 1.1 tooth trauma, restored with resin a month ago. Radiographically, a fairly extensive restoration and a large periapical lesion are observed.

Methods: The patient was diagnosed with acute apical periodontitis. Root canal treatment was undertaken, performing access opening, cleaning, shaping and disinfection of the root canal and placement of calcium hydroxide for 1 month, and subsequent filling

with BioRoot™ RCS sealer and gutta-percha; control examinations were performed at 4, 5 and 7 months.

Discussion: It is interesting to note that although this patient was very young, periodontitis and all its symptoms had been developed within 1 month.

Conclusion: Clinical success of cleaning, shaping, disinfecting and sealing the canal with biocompatible bioceramic sealant.

Introduction

Apical periodontitis may be caused by exogenous or endogenous factors. Exogens may include microorganisms and their toxins, their harmful metabolic by-products, chemical agents, mechanical irritation, foreign bodies, or trauma.

Evidence therefore exists to assert that bacteria are the major etiologic factor in the development of apical periodontitis.(1) As in this particular case, received impact trauma is a primary etiologic factor in the occurrence of periodontitis, and a secondary factor is the bacterial contamination caused by exposure of the dentin tubules to bacteria at the time of the dental fracture; it should be emphasized that the dentin tubules present a clear route to the cavity where the pulp tissue is located, which then becomes necrotic, causing periodontitis.

The success of root canal treatment in apical periodontitis cases depends on adequate cleaning, shaping, disinfection and filling of the root canals.

The primary objectives in cleaning and shaping the root canal system are as follows: a) Remove soft and hard infected tissue. b) Open access for irrigants and to the apical space of the canal. c) Prepare a space for the application of intra-canal treatment and the subse-

quent filling. d) Maintain the integrity of root structures. (2) Root canal sealers are necessary to seal the space between the dentin walls and the interface with the filling material. The sealers also fill bubbles and irregularities in the main, lateral and canal areas, and also fill the spaces between the accessory gutta-percha points used in lateral condensation and serve as lubricants during the filling process. Sealers must be biocompatible and well tolerated by the periapical tissues. (3)

In comparative in vitro studies in periodontal ligament cells, BioRoot™ RCS has been shown to have greater bioactivity than zinc oxide and eugenol; it has also been shown to have fewer toxic effects and to generate increased secretion of antigenic and osteogenic factors. The rapid binding of the sealer to the periodontal ligament result in a visible response of the periodontal ligament cells is visible, showing that this is an appropriate methodology. (4)

This sealer is highly hydrophilic, which provides the advantage of allowing natural humidity in the dental canals and tubes, unlike other sealers, the behavior of which is impacted by humidity. They are dimensionally stable, and do not contract while hardening, but in fact expand slightly, and are insoluble in tissue fluids. (5)

Clinical Case

An 18-year-old female patient presented with pain symptoms. Upon visual and instrumental inspection, we observed a tooth with an extensive resin restoration in the cervical and coronal third, which had been placed after the tooth fractured just over a month ago; she had gone to a dentist 3 days after the fracture occurred. The dentist who treated her told us that he had disinfected the cavity with Consepsis chlorhexidine solution (Ultradent), performed an indirect

capping with TheraCal (Bisco Dental) and restored the tooth with Z250 light-cure resin (3M). He also reported that the tooth was vital at that time, since it responded to cold, heat, and to air from a triple syringe. After restoration, she remained asymptomatic for almost three weeks. Symptom onset occurred at the start of the fourth week, especially when chewing. Always with the examination, palpation and percussion tests were positive, and vita-

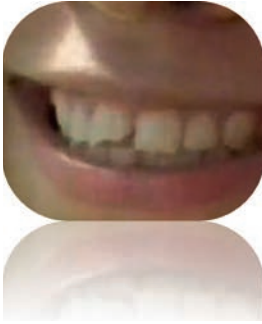
lity tests with cold and heat were negative. Radiographically, a well-circumscribed, substantial lesion was observed. The diagnosis was Acute or Symptomatic Apical Periodontitis.

We proceeded to anesthetize and isolate tooth 1.1, performed antiseptics of the operative field with Isodine, moving from the center of the tooth to the periphery, spanning the clamp and approximately 2 centimeters of the dental dam. Subsequently, we opened an access using a long-shank, ball-shape #4 carbide burr, creating a triangular access cavity; we then proceeded to make a glide path in the canal, using Mani brand RT files, guided by an NSK Ipex II apex locator, and finally obtained a root canal measurement using a #30 RT file at 24 mm, taking a reference point at the incisal edge. Having obtained the root canal measurement, we proceeded to use Gates-Glidden drills at the cervical and middle thirds of the canal from 1 to 5, always recapitulating with the #25 file and irrigating with 1.25% sodium hypochlorite; we then began rotary instrumentation of the canal using the MANI Silk system, in the following sequence: 20/04.25/04.25/06.35/04.30/06.40/04; for the remaining diameters, 45/04 and 04/50 HyFlex tools were used, and manual recapitulation performed with a 45 RT file.

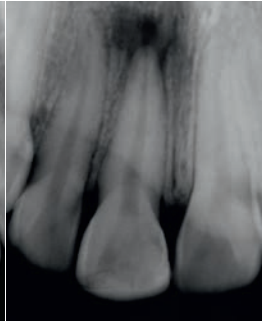
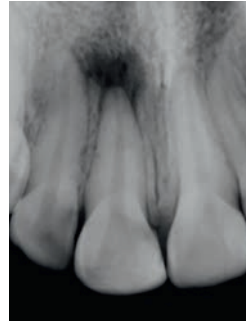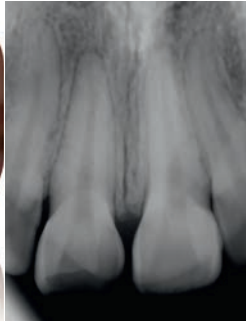A final passive irrigation was then performed with 5% hypochlorite for 5 minutes, followed by irrigation with saline solution; subsequently 17% EDTA was placed for a final irrigation with saline solution; the area was then dried with #45 paper points and recapitulated with a 45 RT tool. Calcium hydroxide mixed with iodoform and propylene glycol was then placed and introduced into the canal using a file 2 sizes smaller than the master file. In this case, a number 35 was used, and medication was left in for 3 weeks. At the next appointment, the patient was anesthetized, isolated, and irrigated with saline solution. The root canal was then dried and filling was performed. A

size 45 gutta-percha point was fitted in and a cone test was performed. The BioRoot™ RCS sealer cement was prepared according to the manufacturer's instructions (I personally use a chilled mixing pad so as to increase the working time of the cement); after placing the powder on the mixing pad using the spoon included in the kit and dividing it into 4 segments, 5 drops of the liquid were added and mixed into the powder segment by segment, using very short spatula movements and continuously rotating the mixing pad to accelerate the mixing process; once this was achieved, finally, one more drop of the liquid was added to obtain the proper consistency for greater cement plasticity, and the consistency checked by drawing out a strand; this entire procedure was performed in one minute. Once the sealer was prepared, the canal was sealed using cold lateral compaction. The #45 gutta-percha master point was then placed with the bio-root sealer and brought to the depth previously sounded with a pumping motion to allow the sealant to settle free of any bubbles. A previously calibrated MA57 spacer was then used for lateral gutta-percha condensation to accommodate the Fine-Fine accessory cones, which were put in with sealer as well; condensation was verified by an obturation X-ray test, and then the protruding points were severed using a 33L spoon heated directly in a burner flame; vertical compaction was performed, a D11 spacer placed in the center of the gutta-percha mass, obturation performed with a medium point, and the excess cut off using the 33L spoon, and one last vertical condensation conducted using a Glick #1 tool. The cavity was then cleaned with an alcohol swab and a sterile Teflon swab, and Cavit was placed as a provisional restoration.

The patient was referred to her dentist for the subsequent final restoration. Clinical and radiographic controls were performed at 4, 5, and 7 months.



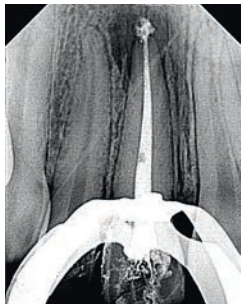Post-trauma preoperative X-ray 05/07/2019, 1 month prior to treatment.



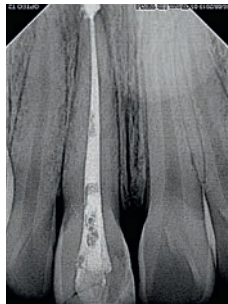Preoperative X-rays the day treatment began, 16/08/2019.



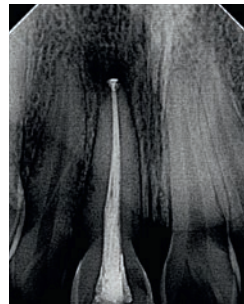Radiographic root canal measurement. 16/08/2019.



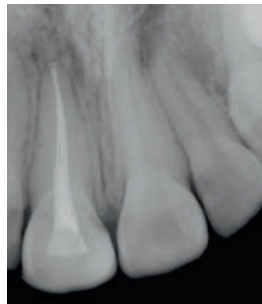Intra-canal medication 16/08/2019.



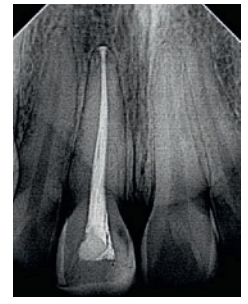
Intra-canal medication prior to obturation, 16/08/2019.



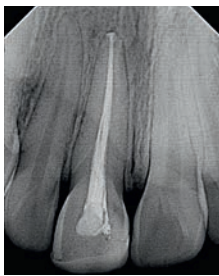Lateral obturation technique, using gutta-percha and BioRoot™ RCS sealer, 10/09/2019.



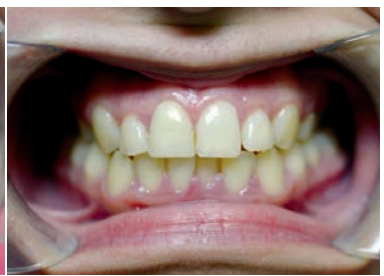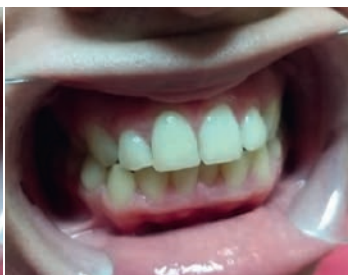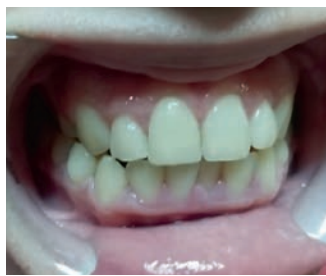1st clinical-radiographic control at 4 months, 22/01/2020.



2nd clinical examination X-ray 5 months, 24/02/2020.



3rd clinical examination. 7 months. X-ray. 07/04/2020.



Clinical photographs. 07/04/2020.

Discussion

The etiology, pathogenesis, and histopathology of apical periodontitis are similar to those of marginal periodontitis. Both diseases are caused by bacterial infection and involve pathological changes in the alveolar bone, the periodontal ligament and the cementum. Marginal periodontitis affects the coronal periodontal tissues, while apical periodontitis affects the apical periodontal tissues. Bone loss is one of the characteristic factors in both diseases; bone crest is lost in marginal periodontitis, and apical bone undergoes resorption in apical periodontitis. (1)

A major biological goal of root canal therapy is the management of apical periodontitis through the disinfection and subsequent sealing of the root canal system; in terms of the traditional concepts used in endodontic therapy, the cleaning then shaping of root canals was for many years considered the proper order; it has now emerged that it is appropriate to reverse the order typically applied, and instead first shape and then clean; the current concept is shaping with new instrumentation systems, and most practitioners now favor the preparation of

canals with a greater taper and the conservation of more of the tooth structure, implementing cleaning through the irrigation of the canals with different techniques and implements, whether passive, sonic or ultrasonic. (2)

In regard to immediate intra-canal medication with Calcium Hydroxide in teeth presenting apical periodontitis, Dr. Safavi has reported that exposure of bacterial lipopolysaccharides (lps) to calcium hydroxide causes hydrolysis of

the lipid component, resulting in endotoxin degradation.

An important complement to the obturation of root canals is the use of a good endodontic sealer. Tricalcium silicate-based sealers exhibit proven bioactivity in the presence of tissue fluids, with the deposition of hydroxyapatite ions on the surface of the material. This bioactivity induces the formation of hard tissue and the healing of connective tissue. (6)

Conclusion

Success in the repair process subsequent to a root canal treatment is measured by the absence of the clinical signs and symptoms of a persistent periapical condition. The definitive measure of success, however, is periapical repair, because the goal of treatment is the resolution of periapical disease. Clinical assessment of a successful treatment is based on the absence of signs of infection and inflammation such as pain; percussion sensitivity; tenderness to the palpation of the surrounding periapical tissues; absence of inflammation or sinus tract, and above all the radiographic demonstration of a reduction in the size of the periapical lesion. Most periapical lesions repair within the first year; depending on the size of the injury, repair may continue for up to four years or more. (7)

In this particular case, the trauma caused by the dental fracture and the exposure of the dentin to the oral environment for 3 days were most likely the cause of the impending pulp necrosis and the rapid development of symptomatic apical periodontitis.

Sealing the root canal system is a very important part of endodontic treatment, and using a bioactive sealer is essential to ensure a successful one. Tricalcium silicates are highly hydrophilic which provides the advantage of allowing natural humidity in the dental canals and tubules, unlike other sealers, the behavior of which is impacted by humidity. They are dimensionally stable, and do not contract while hardening, but in fact expand slightly, and are insoluble in tissue fluids. (5)



Author:

Dr. Antonio Fernando Herrera de Luna

Oral surgeon, graduated from the Technological University of Mexico in 1986.

Post-graduate work in endodontics at the Oral Rehabilitation Research and Specialization Center (CIERO) from January 1987 to July 1988.

Residency at the department of endodontics, Mogi-das Cruces University-Sao Paulo, Brazil, from January to July 1991.

Professor of endodontics and research professor at the College of Dentistry of the Valle de Mexico University, Reynosa campus, from 2000 to December 2017.

Ex-professor in theory and clinical work in the postgraduate endodontics program at UANL.

Licensed; 1st, 2nd, 3rd and 4th recertification by the Mexican Endodontics Council.

Member of the ADM (Mexican Dental Association) since 1992.

Member of AME (Mexican Endodontics Association A.C.) since 1995.

Lecturer at AME.

President of the Mexican Association of Endodontics, College of Endodontics Specialists, A.C. two-year term June 2013-June 2015.

Various publications in the Endodontics Field in the magazine of the Mexican Dental Association (ADM) and in the magazine of the Mexican Endodontics Association (AME).

Participated as an international lecturer on the subject of endodontic regeneration, presenting in:

- Japan at the World Endodontic Congress in May 2013 (IFEA).
- Brazil at the Congress of the Brazilian Endodontic Society and the Latin American Endodontic Society (SELA) in November 2014.
- Barcelona at the Congress of the European Endodontic Society (ESE), September 2015.

Visiting professor for the postgraduate program in endodontics at the autonomous university of Yucatan and Ciudad Juarez.

"Dr. Fernando Campuzano" medal, awarded by the College of Oral Surgeons of Reynosa, A.C. in February 2004.

"Dr. Fernando Campuzano Odontological Merit Award", awarded by the National Council of the ADM, August 2009.

"Teaching Career Prize" awarded by Valle de Mexico University, Reynosa campus, December 5, 2013.

Egregius academic excellence award for educational work granted by Valle de Mexico University, Reynosa campus, October 20, 2017.

Presented at more than 100 conferences at the national and international level.

Exclusive private endodontics practice from 1989 to date in the city of Reynosa Tamaulipas.

Conference topics:

1. Bioactive cements.
2. Cleaning and shaping of root canals with cutting edge instruments.
3. Endodontic regeneration: current concepts and clinical cases.
4. Endodontic diagnosis and pulp and periapical pathology.

References

1. Lin Louis M; Huang George T.J; Pathobiology Of Apical Periodontitis; Chapter 15; Pages 631-632. Cohen's Pathways Of The Pulp. Eleventh edition. Kenneth M. Hargraves, Louis H Berman. Editor - Ilan Rotstein. Elsevier 2016.
2. Peters Ove. A; Peters Christine I.; Basrani Bettina. Cleaning And Shaping The Root Canal System. Chapter 6. Page 210. Cohen's Pathways Of The Pulp. Eleventh edition. Kenneth M. Hargraves, Louis H Berman. Editor - Ilan Rotstein. Elsevier 2016.
3. Johnson William; Kulild James C; Tay Franklin; Obturation Of The Cleaned And Shaped Root Canal System. Chapter 7. Page 290. Cohen's Pathways Of The Pulp. Eleventh edition. Kenneth M.hargraves, Louis H Berman. Editor - Ilan Rotstein. Elsevier 2016.
4. Camps Jean; Jeanneau Charlotte; Laurent Patrick; About Imad. Bioactividad Del Sellador Endodontico A Base De Silicato De Calcio-Bio-Root-Rcs.interacciones Con Celulas Humanas Del Ligamento Parodontal – Estudio In Vitro. [bioactivity of BioRoot-RCS calcium silicate based endodontic sealer. Interactions with human periodontal ligament cells - in vitro study] Journal of Endodontics. A.A.E. 2015.
5. Trope Martin; Bunes Alf; Debelian Gilberto; Root Filling Materials And Techniques, Bioceramics A New Hope. Endodontics Topics, 2015. Vol 32. Pages 86-96.
6. Arias Moliz MT; Camilleri J. The effect of the final irrigant on the antimicrobial activity of root canal sealers. Journal of Dentistry. 2016 Elsevier, Ltd.
7. Xuan-Li NG; Gulavibala K. Evaluation Of Outcomes. Chapter 11. Pages 478. Cohen's Pathways Of The Pulp. Eleventh edition. Kenneth M. Hargraves, Louis H Berman. Editor - Ilan Rotstein. Elsevier 2016.



Maxillary Sinusitis of Endodontic Origin non-surgical management

Pamela Rebeca Mora Favela (Dental Surgeon)¹, Ignacio Jiménez Bueno (Masters in Endodontics)², Brissa Itzel Jiménez Valdés (Masters in Normative and Forensic Stomatology)³

Autonomous University of the State of Mexico, Faculty of Odontology, Centre for Research and Advanced Studies in Odontology, Endodontics postgraduate.

Summary

Introduction: Maxillary Sinusitis of Endodontic Origin (MSEO) is a fast-spreading and potentially fatal infectious process that can be resolved non-invasively with timely diagnosis and treatment.

Clinical Case: 17-year-old female patient presenting with yellowish and foul-smelling nasal discharge, hemifacial pain, and hyperthermia. On inspection, tooth 26 was observed as having a large cavity and being sensitive to intra- and extraoral palpation, as well as to horizontal and vertical percussion. A necropulpectomy was performed using the hydraulic sealing technique and BioRoot™ RCS

(root canal sealant). A pharmacological treatment was introduced in cooperation with the ENT department.

Discussion: With the use of diagnostic aids, interviews, procedures, and use of appropriate bioceramic materials, orthograde endodontic treatment provides an effective non-surgical alternative.

Conclusions: The use of bioceramic materials such as BioRoot™ RCS improves the effectiveness of non-invasive treatment by providing a hermetic seal in the apical zone.

Introduction

Maxillary Sinusitis of Endodontic Origin is an inflammatory response of the maxillary sinus mucosa to pathogenic agents originating from a dental organ (Tataryn, 2018). The spread of odontogenic infectious processes towards craniofacial anatomical areas has been documented since 1943 by Bauer, and it has been discovered over the years that it is more common than has been recognised (AAE 2018). Some other authors, like Abrahams, have asserted that approximately 60% of cases of pulp necrosis in upper molars present this pathology (Abrahams, 1996). This change can be brought about by infectious agents generated by necrosis of the pulp with subsequent development of apical abscess which, when perforating the layer of bone that forms the maxillary sinus floor, penetrates into this space and produces various clinical and radiographic signs and symptoms (Duzgun, 2013). During its progression, the inflammation of the antral mucosa will obstruct the cavity, displaying symptoms compatible with rhinosinusitis. The inflammation may not be limited to the maxillary sinus but may expand to more vulnerable areas such as the nasal cavity,

the ethmoid and frontal sinuses, in severe cases even affecting the orbital cavity, which can lead to orbital cellulitis, blindness, meningitis, brain abscess, and cavernous sinus thrombosis (Obayashi, 2004).

Timely detection of this entity permits a minimally invasive approach in conjunction with individualised pharmacological treatment consistent with the symptomatology and general condition of the patient (Rosenfeld, 2015), as well as using three-dimensional sealing techniques with bioceramic materials. The objective of these materials is a biological approach where they interact with the dentin in the root canal, resulting in minimising porosity compared to the lateral condensation technique (Moinzadeh, 2015). This also allows us to achieve a gutta-percha-dentin interface with dimensional stability, antimicrobial potential, and bioactivity, with the ability to stimulate the repair of the periapical tissue (Trope, 2014) as it has calcium-releasing properties, alkalinising activity, and the ability to form apatite. (Siboni, 2017).

Clinical case

A 17-year-old female patient attended the Postgraduate Endodontics Clinic at UAEMex, referred by her private Odontologist for presenting with slight pain on mastication. During the interview she said that she had left hemifacial pain, which increased when leaning, as well as also presenting with yellow and foul-smelling nasal discharge and episodes of hyperthermia progressing over two weeks. The patient said she was allergic to Penicillin.

During extraoral exploration, there was sensitivity to palpation in the left lower third of the face (maxilla) and superciliary area; on intraoral exploration, tooth 26 was identified as having a

large cavity (*Fig.1*), grade 1 mobility, sensitivity to horizontal and vertical percussion, and

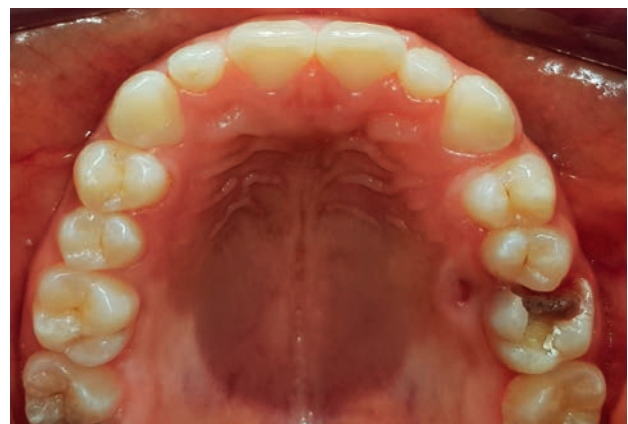

Fig. 1: Occlusal intraoral photograph where the cavity can be seen in tooth 26.

negative responses to thermal sensitivity tests. Periapical radiography was taken (Fig.2) and CBCT 5x5 (Fig.3) requested. Once collected, all the tests confirmed a diagnosis of pulp necrosis with a chronic apical abscess with drainage to the maxillary sinus, which was also causing Maxillary Sinusitis of Endodontic Origin.

The canals were treated in one session after suitable complete isolation. The operating field was disinfected with 5.25% NaOCl, caries were removed, and the disinfection procedure was repeated. Once access was gained to the pulp chamber, it was neutralised with 5.25% NaOCl. The canals were located and permeated with a K Flexofile #15.02, the working length was obtained with foramen locator DPex III (Wood Pecker), and the instrumentation mechanised with the ProTaper Universal system (mesial and distal canals as far as F2, palatal canal F3). With continuous irrigation with NaOCl 5.25% and EDTA 17%, the canals were sealed afterwards

by hydraulic condensation technique using BioRoot™ RCS as a sealing cement (Fig.4 and 5).

A cross-discipline consultation was carried out with the Otorhinolaryngology department, which began pharmacotherapy due to rhinorrhoea and a change in the general condition of the patient. It consisted of Levofloxacin 500 mg / 24 hours / 7days, Ambroxol 30 mg / 8 hours / 10 days, Oxymetazoline 2 sprays / 12 hours / 7 days, as well as thermotherapy and continuous nasal irrigation with saline solution. It was restored with a Biodentine™ core and afterwards a resin overlay-type restoration was placed (Fig.6).

The symptomatology subsided completely seven days after treatment and has remained asymptomatic to date. During the follow-up appointments with CBCT at 3 (Fig.7) and 8 months (Fig.8), gradual positive development of the mucosa and the maxillary sinus floor was observed.

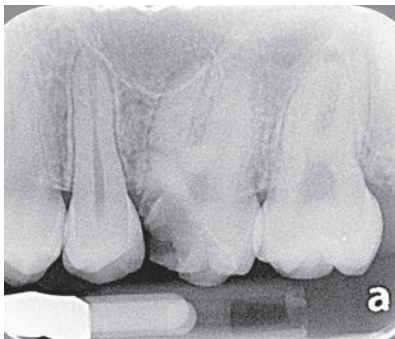


Fig. 2: Initial orthograde radiography.

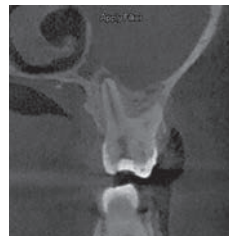

Fig. 3: CBCT 5x5 with axial view where an increase in maxillary sinus mucosa and nasal turbinates (mucositis) volume can be observed, as well as loss of continuity in the maxillary sinus floor.

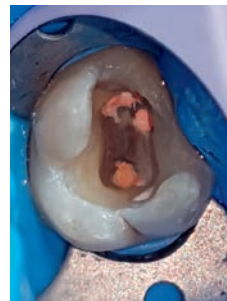

Fig. 4: Intraoral photograph of treatment of canals sealed with BioRoot™ RCS.

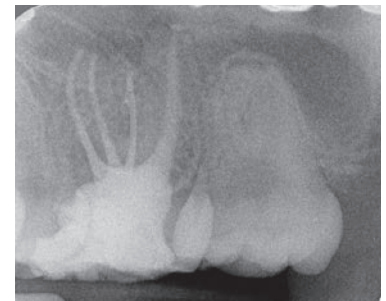

Fig. 5: Final mesioangular radiography showing the palatal, distal, mv1, and mv2 canals sealed along the working length with presence of sealer puff in the palatal canal.

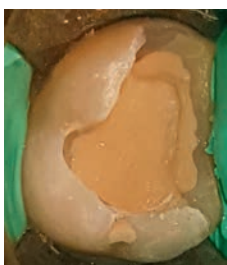

Fig. 6: Intraoral photograph of the core with Biodentine™.

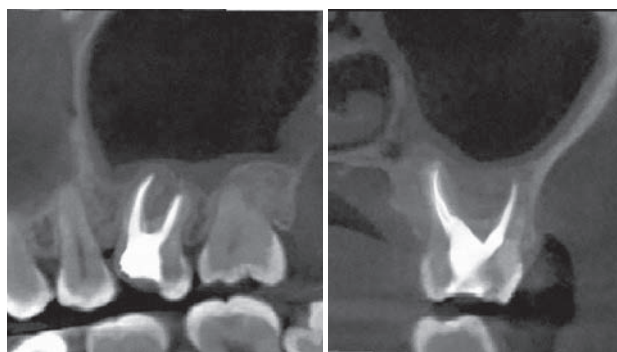


Fig. 7: CBCT 5x5 control examination at 3 months showing thinning of the antral mucosa as well as bone repair.

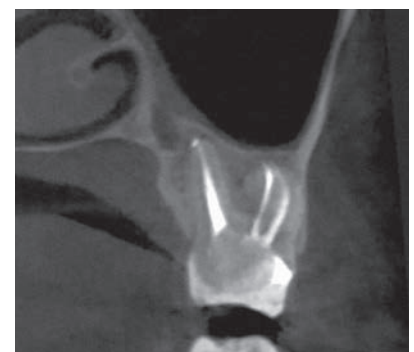


Fig. 8: CBCT 5x5 control examination at 8 months; the patient remains asymptomatic.

Discussion

The objective of treating root canals is to foster a suitable environment so that periradicular lesions and the affected anatomical areas can recover, thus avoiding more invasive treatments. Non-surgical treatment of early stage Maxillary Sinusitis of Endodontic Origin offers the patient a non-invasive and rapid progress option (Kretzschmar, 2003). It is very important to use CBCT to assess the anatomical structures involved, the condition of the antral mucosa, the bony part of the maxillary sinus floor, and to confirm our diagnosis.

The development of canal treatment with a suitable isolation technique, chemical-mechanical disinfection, and three-dimensional sealing is crucial to the success of the treatment. Using a sealant that allows us to obtain a three-dimensional seal is essential, which is why relatively recent materials such as bioceramics

are chosen. In this case it was BioRoot™ RCS, which is composed of silicate and calcium phosphate, providing physical and biological properties such as an alkaline pH environment, antibacterial activity, and is a biocompatible material. (Maillet, 2011)

Using a hydraulic condensation technique provides a three-dimensional seal, ensuring the minimal presence of spaces between sealant, gutta-percha, and dentin. Similarly, its alkaline properties provide an environment where micro-organisms will not thrive, as well as avoiding having to use the kind of force during sealing that could encourage the appearance of radicular fissures or fractures. These properties result in the disappearance of symptoms in a period of 7 days and positive development at 8 months.

Conclusion

Given the high percentage of cases that can develop in this way (MSEO) and how often they are overlooked, it is important for all clinical practitioners, odontologists, physicians, and radiologists alike, that they are thoroughly familiar with the close relationship between the paranasal sinuses and the oral structures, in order to be able to arrive at a more accurate and timely diagnosis. The use of diagnostic aids, such as computerised tomography or orthopantomography, is essential for confirming this. The patient's systemic condition, as well as their age and progression of the illness,

will be instrumental in choosing an adjuvant pharmacological treatment and its complexity.

The use of the hydraulic sealing technique with BioRoot™ RCS not only facilitates this stage of the treatment, providing sufficiently long handling times to manage it (approximately 12 minutes), but also allows us to adapt the consistency to the specific needs of each case, and can provide a more liquid or solid mixture as necessary. Similarly, its antimicrobial properties provide the ideal environment to heal periapical tissues quickly.

Authors:



Pamela REBECA MORA FAVELA

Dental Surgeon

Degree in Dental Surgery from the Autonomous University of the State of Mexico, 2008.
Private General Odontologist from 2009 to present.

Third semester student in Endodontics Postgraduate, Autonomous University of the State of Mexico.



Ignacio JIMÉNEZ BUENO

Masters in Endodontics

Degree in Dental Surgery from the Autonomous University of the State of Mexico, 1985.

Specialisation in Endodontics in the Autonomous University of the State of Mexico, 1994.

Masters in Endodontics from the Yury Kuttler Institute for Advanced Odontology Studies, 2012.

Endodontics Postgraduate Coordinator, Autonomous University of the State of Mexico.



Brissa ITZEL JIMÉNEZ VALDÉS

Masters in Normative and Forensic Stomatology

Degree in Dental Surgery from the Autonomous University of the State of Mexico, 1997.

Specialisation in Endodontics in the Autonomous University of the State of Mexico, 1999.

Masters in Normative and Forensic Stomatology, University of Valle de Toluca, 2019.

Lecturer, Endodontics Postgraduate, Autonomous University of the State of Mexico.

References

1. Tataryn RW, (2018) Maxillary Sinusitis of Endodontic Origin, AAE, Colleagues for Excellence.
2. American Association of Endodontists, (2018). AAE position statement: Maxillary Sinusitis of Endodontic ORIGIN, Journal of Endodontics.
3. Abrahams JJ, Glassberg RM. (1996) Dental disease: a frequently unrecognized cause of maxillary sinus abnormalities? Am J Roentgenol.
4. Duzgun Yildirim, Murat Eroglu, Murat Salihoglu, (2013). The Relationship between Dental Indentation and Maxillary Sinusitis, Open Journal of Medical Imaging.
5. Obayashi N et al, (2004). Spread of Odontogenic Infection originating in the maxillary teeth: computerized tomographic assessment, Oral Surgery, Oral Medicine, Oral Pathology.
6. Rosenfeld RM, et al, (2015). Clinical practice guideline (update): Adult sinusitis executive summary. Otolaryngol Head Neck Surg.
7. Moizadeh AT, Zerbst W, Boutsoukis C, (2015) Porosity distribution in root canals filled with gutta percha and calcium silicate cement. Dent Materials
8. Trope, M., & Debelian, G. (2014). Bioceramic Technology in Endodontics. Inside Dentistry.
9. F. Siboni, P. Taddei, F. Zamparini, C. Prati & M. G. Gandolfi. (2017). Properties of BioRoot™ RCS, a tricalcium silicate endodontic sealant modified with povidone and polycarboxylate, International Endodontic Journal
10. David P. Kretschmar, DDS, MS,a and Colonel James L. Kretschmar. (2003) Rhinosinusitis: Review from a dental perspective, Oral Surgery, Oral Medicine, Oral Pathology.
11. Maillet M, Bowles WR, McClanahan, SL.(2011) Cone-Beam computed tomography evaluation of maxillary sinusitis. Journal of Endodontics.

BioRoot™ RCS

Indications: Permanent root canal filling in combination with gutta-percha points in case of inflamed or necrotic pulp.

Permanent root canal filling in combination with gutta-percha points following a retreatment procedure. BioRoot™ RCS is suitable for use in single cone technique or cold lateral condensation.



Periapical healing: BioRoot™ RCS Bioactive potential

Authors: Dr. Rocco Zaccone, Dr. Patrizio Galeano
Endodontic Denstritry - University of Rome - Italy.
AIE Active members.

Summary

In this case report, we will talk about the properties and regenerative capacity of BioRoot™ RCS. In addition to the antibacterial and biocompatibility properties, bioceramics are characterized by a very important regenerative capacity. In this case

of a 3.6 retreatment of an extensive periapical lesion, we have used BioRoot™ RCS: we noticed an extremely rapid recovery considering that only 8 months have elapsed between the first and the last X-Ray.

Introduction

Primary endodontic treatment does not always result in clinical success.

The causes? They may be multiple and determined by three main consequences:

- 1) An incomplete cleaning / shaping / filling of the root canals
- 2) The presence of radiologically visible lesions
- 3) Pain of the patient during percussion, palpation and chewing.

Retreatment is the best therapeutic approach to solve these clinical situations, if well performed, with a success rate of 85%, as reported in the articles. This procedure has the purpose

of shaping, cleaning and filling the parts that have been treated with the aim of reducing the contamination of the bacteria present in the root canals and responsible for endodontic lesions.

When should retreatment be done?

- 1) Presence of radiologically visible lesions
- 2) Presence of iatrogenic damage
- 3) Presence of an incongruous treatment, even in the absence of symptoms, if on the same session we have to do a prosthetic rehabilitation
- 4) Persistent pain symptoms even in the absence of injury.

What are the various phases that characterize retreatment?

- 1) Isolation with rubber dam
- 2) Removal of the previous restoration and of any carious tissue
- 3) Obtaining a correct access to the canal system
- 4) Removal of the materials present inside the endodontic space
- 5) Shaping, cleaning and filling of the root canal.

The success rate in retreatment is certainly lower than in the primary treatment as we can find some bacterial species within the canals, such as the *Enterococcus faecalis* and the *treponema denticola*, which are much more resistant to the various mechanical and irrigation phases which characterize a retreatment and also for their ability to penetrate the dentinal tubules.

Therefore the success rate can be considerably increased by using materials that guarantee both an intimate adhesion to the canal walls and

a long-term stability. Before, the gold standard of the endodontic seal was represented by the vertical hot condensation of Schilder. But today, the tendency is to believe that the cold closure with single cone associated the bioceramic cement can guarantee us the three-dimensional stability of the long-term endodontic seal that we are constantly searching for.

In fact, with hot sealing, the gutta percha contracts as it gets cold, creating a gap between itself and the walls of the canal, which over time will potentially allow any residual bacteria to re-colonize the endodontic space; instead the bioceramics, as in this clinical case presented and treated with the BioRoot™ RCS (Septodont), are cements that have advantages such as:

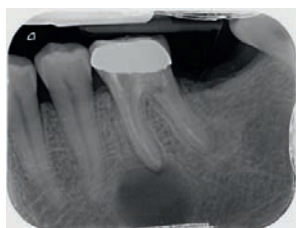
- 1) No presence of resin therefore no retraction
- 2) No vacuum in the interface
- 3) No tubular infiltration
- 4) Hydroxyapatite formation and dentin mineralization.

Clinical case

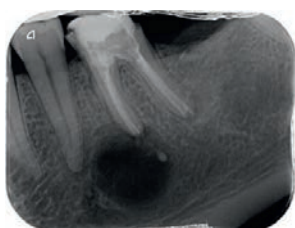
39-year-old male MLR Caucasian patient reported by a colleague who could not completely remove a fiber post in the distal root; he was performing retreatment because the root canals, under X-ray examination, appeared to be undersized and under-prepared. (X-ray 1) The patient complained of pain during palpation and percussion, and the clinical picture showed the presence of an active vestibular fistula. The radiographic examination shows an extended periradicular lesion of the mesial root. (X-ray 2) Once the operating field is isolated, the pin is removed from the distal root through the use of the operating microscope which had previously

been neither found nor treated; at the same time the old filling material is removed from the canals m.v and m.l. , which turned out to be undersized in the preparation, creating an adequate preparation under continuous alternate washes of hypochlorite and EDTA at 17% constantly activated with sonic tips.

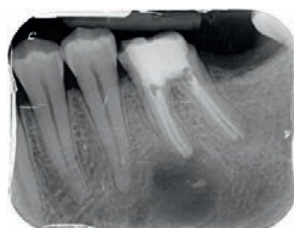
The closure of the root canals was performed cold with gutta-percha cones, chosen according to the new canal preparation, and BioRoot™ RCS. The X-rays made at 3 and 5 months after the closure show that, even after a very short time, there was a complete healing of the bone. (X-ray 3 and X-ray 4)



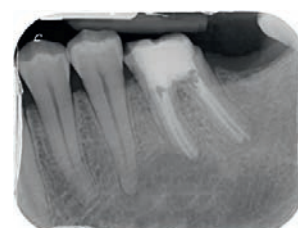
X-ray 1



X-ray 2



X-ray 3



X-ray 4

Discussion

Bioceramics are today quite known materials in the literature, mainly because they represent an important step forward in the search for the ideal root canal sealer. The BioRoot™ RCS guarantees us innumerable properties including extraordinary sealing capacities, antimicrobial activity that stimulates periapical healing. It is a bioactive material that continues to produce hydroxyapatite for a long time after mixing, adapting to the dentinal walls and optimizing its sealing capacity. This is a very interesting material because it adheres very well to both dentin and gutta-percha, therefore it can be used in cold closing techniques. How is it used? Once the cone is prepared according to the diameter. We have to cut it to the proper working length. Then, we mix the powder with the liquid to obtain a viscous / fluid consistency.

Subsequently the cone is wet with the mix and inserted several times until the root canal is submerged by the cement and the surfaces of the master cone are completely covered by the same. In this way we will be sure that the BioRoot™ RCS cement will seal the apical portion of the canal where the greatest chances of endodontic success are played. Cold closure, using any other endodontic cements on the market can be absorbed over time, and it has always been considered an ineffective technique. On the other hand, with the discovery of bioceramics, the cement plays a crucial role because it permanently seals the root canal including the apex. The gutta-percha cone - which must be brought up to the apex - has the function of being only a guide for possible future retreatment.

Conclusion

The case described above shows us how BioRoot™ RCS, thanks to its ability to firmly adhere both to the gutta-percha and to the walls of the canal definitively seals the apical third, which allow us to obtain healing in a short

amount of time by its antimicrobial properties. However, further clinical studies must be performed to assess the effectiveness of this technique on the long term.



Authors:

Dr. Rocco Zaccone

Doctor Rocco Zaccone is specialized in the use of the operating microscope and he practices his profession in many cities in Italy, especially in Rome, Capri and Florence.

Professor at the Post-graduate Master of the "Catholic University of the Sacred Heart" in Rome, he keep working as tutor at the Endodontics department of the Polyclinic Agostino Gemelli of Rome.

He holds the role of active member of AIE (Italian Endodontics Academy) and he founded together with Prof. Grande, Dr. Galeano and Dr. Del Giudice the "Francesco Riitano Study Group".

Speaker at national courses and conferences, he spends his free time looking for new dental techniques.



Dr. Patrizio Galeano

Graduated with honors in Dentistry and Dental Prosthesis from the University of Rome "Tor Vergata" in 2005.

From 2001 to 2014 Dr Galeano participated in the clinical, didactic activity of the chair of Dentistry Conservative and Endodontics of the same University.

Active Member of the Italian Academy of Endodontics (AIE).

Ordinary member of the European Endodontic Society (ESE).

Ordinary member of the Italian Academy of Conservation (AIC).

He holds the role of tutor at the International Master in Endodontics at the Catholic University of the Sacred Heart in Rome and lecturer at the ASO course in Rome directed by Igea Media.

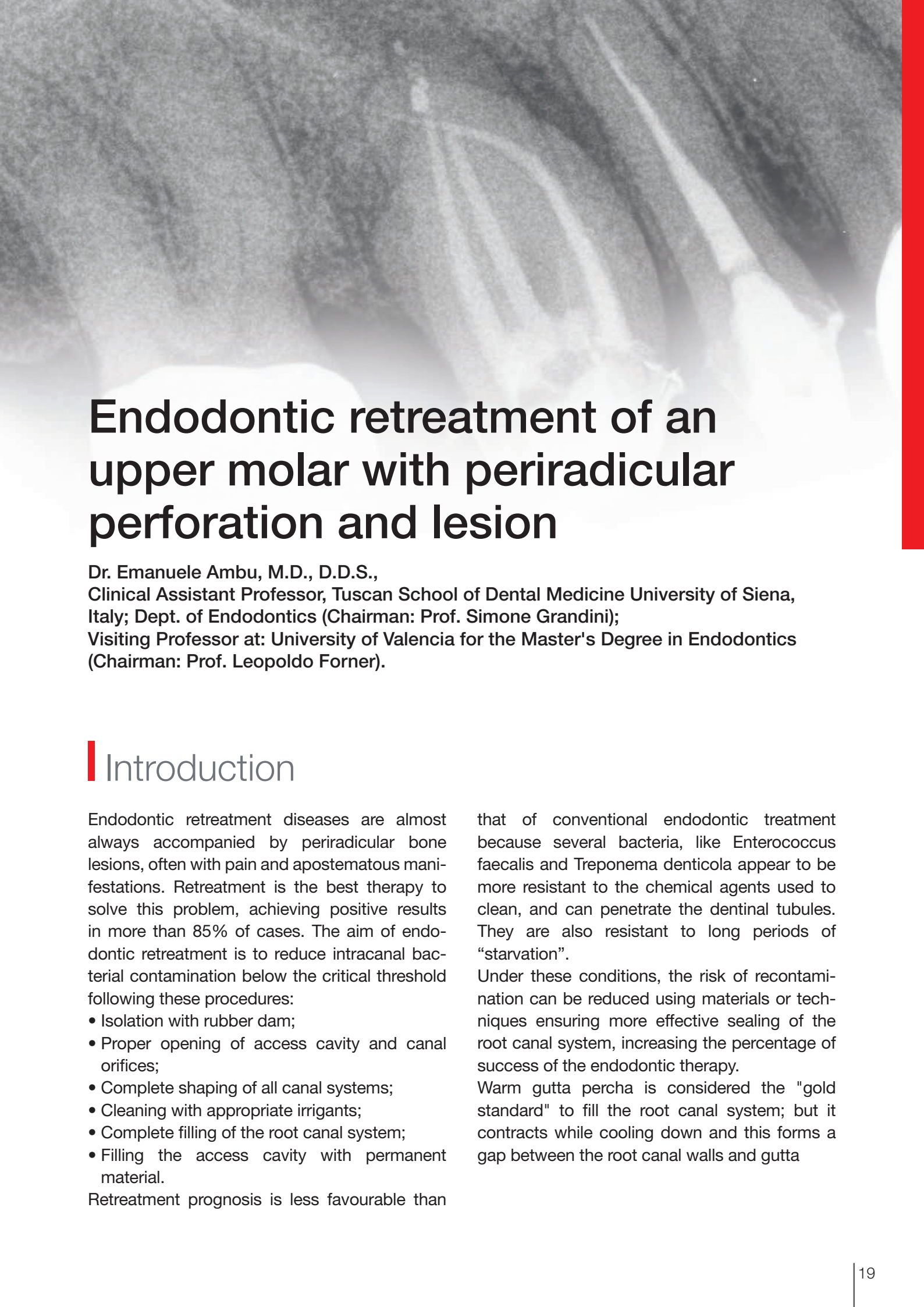
Founding member of the study group "Francesco Riitano".

Speaker at national courses and conferences.

He carries out his freelance activity with particular interest in the fields of Endodontics and Restoration.

References

1. Viapiana R, Moynzadeh AT, Camilleri L, Wesselink PR, Tanomaru Filho M, Camilleri J. Porosity and sealing ability of root fillings with gutta-percha and BioRoot™ RCS or AH Plus sealers. Evaluation by three ex vivo methods. *Int Endod J.* 2016;49(8):774-82.
2. Camps J, Jeanneau C, El Ayachi I, Laurent P, About I. Bioactivity of a Calcium Silicatebased Endodontic Cement (BioRoot™ RCS): Interactions with Human Periodontal Ligament Cells In Vitro. *J Endod.* 2015;41(9):1469-73.
3. Jeong JW, DeGraft-Johnson A, Dorn SO, Di Fiore PM. Dentinal Tubule Penetration of a Calcium Silicatebased Root Canal Sealer with Different Obturation Methods. *J Endod.* 2017;43(4):633-637.
4. McMichael GE, Primus CM, Opperman LA. Dentinal Tubule Penetration of Tricalcium Silicate Sealers. *J Endod.* 2016;42(4):632-6.
5. Alshehri M, Alamri HM, Alshwaimi E, Kujan O. Micro-computed tomographic assessment of quality of obturation in the apical third with continuous wave vertical compaction and single match taper sized cone obturation techniques. *Scanning.* 2016;38(4):352-6.
6. Donnermeyer D, Bunne C, Schäfer E, Dammaschke T. Retreatability of three calcium silicate-containing sealers and one epoxy resin-based root canal sealer with four different root canal instruments. *Clin Oral Investig.* 2017 Jun 22. doi: 10.1007/ s00784-017-2156-5. (Epub ahead of print)



Endodontic retreatment of an upper molar with periradicular perforation and lesion

Dr. Emanuele Ambu, M.D., D.D.S.,
Clinical Assistant Professor, Tuscan School of Dental Medicine University of Siena, Italy; Dept. of Endodontics (Chairman: Prof. Simone Grandini);
Visiting Professor at: University of Valencia for the Master's Degree in Endodontics (Chairman: Prof. Leopoldo Forner).

Introduction

Endodontic retreatment diseases are almost always accompanied by periradicular bone lesions, often with pain and apostematous manifestations. Retreatment is the best therapy to solve this problem, achieving positive results in more than 85% of cases. The aim of endodontic retreatment is to reduce intracanal bacterial contamination below the critical threshold following these procedures:

- Isolation with rubber dam;
- Proper opening of access cavity and canal orifices;
- Complete shaping of all canal systems;
- Cleaning with appropriate irrigants;
- Complete filling of the root canal system;
- Filling the access cavity with permanent material.

Retreatment prognosis is less favourable than

that of conventional endodontic treatment because several bacteria, like *Enterococcus faecalis* and *Treponema denticola* appear to be more resistant to the chemical agents used to clean, and can penetrate the dentinal tubules. They are also resistant to long periods of "starvation".

Under these conditions, the risk of recontamination can be reduced using materials or techniques ensuring more effective sealing of the root canal system, increasing the percentage of success of the endodontic therapy.

Warm gutta percha is considered the "gold standard" to fill the root canal system; but it contracts while cooling down and this forms a gap between the root canal walls and gutta

percha so that the bacteria of dentinal tubules can contaminate canals again.

To solve this problem, a cold-filling technique based on bioceramics has been recently introduced. This material was initially suggested to replace mineral trioxide aggregate in various cases (radicular perforations, apexifications, direct capping of the pulp, etc.), because MTA had some problems: it took long to harden and it was unsuitable to be in touch with the oral environment.

Clinical case

A male Caucasian patient VL aged 48 was referred by a colleague who did not manage to probe the root canals, after many attempts, had not succeeded in probing the canals of his right upper molar, which had been unadequately filled during previous treatments. There was also a perforation altering the pathway of the mesio-vestibular canal. The clinical picture was further complicated by two vestibular fistulae secreting pus. Endoral RX and CBCT examination (*Fig. 1*) -- performed to better understand the functioning of root canals -- showed widespread periradicular lesions and an inflammation of the male breast, with likely odontogenous origin.

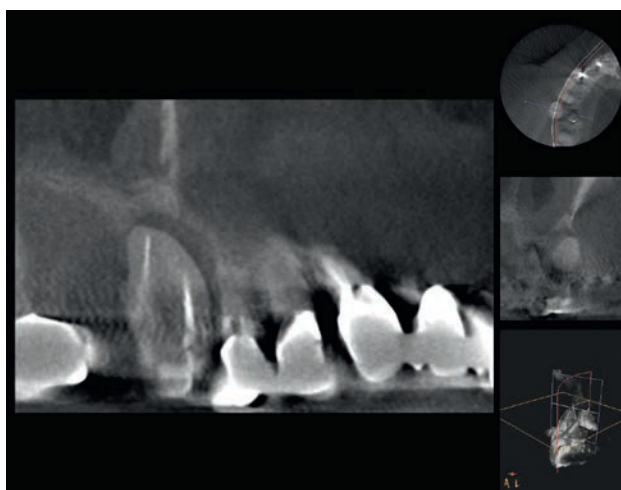


Fig. 1

More recently, a new preparation has permitted the use of bioceramics as an endodontic filling material.

The aim of this paper is to describe a complex example of molar retreatment treated by means of BioRoot™ RCS, a canal filling material sold by Septodont (Saint-Maur-des-fossés, France).

While the palatal and mesio-vestibular canals were easily renegotiable, it was not possible to restore the correct course of the mesio-vestibular canal. Using a surgical microscope, it was possible to locate the orifice of the mesiopalatal canal (*Fig. 2, arrow*), not detected in the two preceding treatments. This canal was found to be confluent with the mesio-vestibular, thus permitting recovery of the entire course, which appeared anomalous compared to the usual endodontic anatomy of the first upper molar.

Following a thorough cleaning of the root canal system, the practitioner filled the entire system using cold tapered gutta percha points (06) and

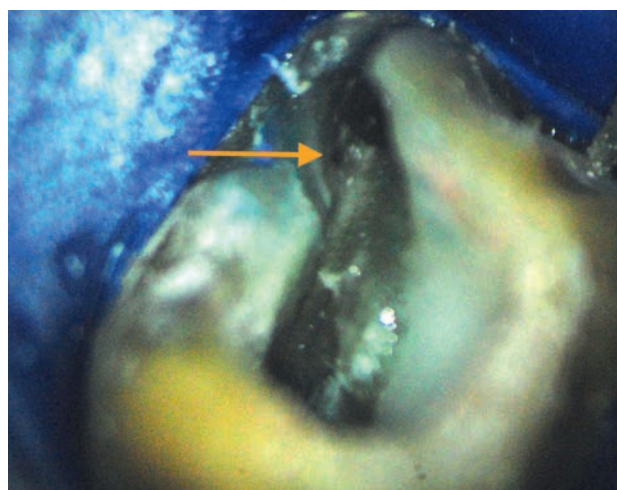


Fig. 2

BioRoot™ RCS cement (*Fig. 3*). The control after seven months showed that the periradicular lesion had almost disappeared and the

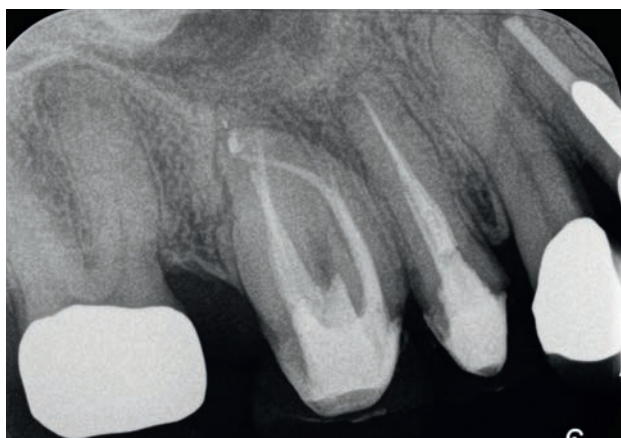


Fig. 3

renewed pneumatisation of the maxillary sinus (*Fig. 4*). Subsequent examination is anticipated 12 months after completion of treatment.

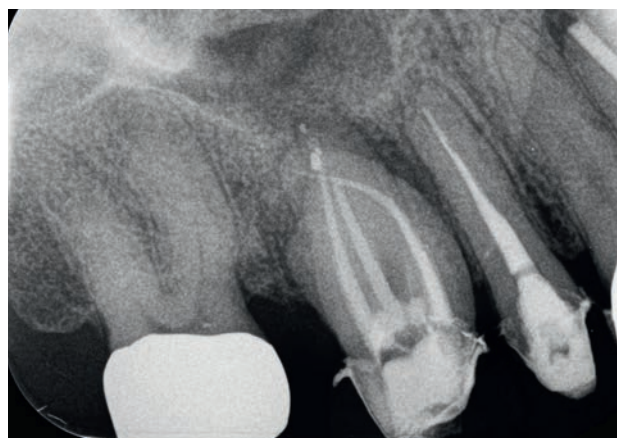

Fig. 4

Discussion

Bioceramics are today quite well-known materials in the literature, especially because they can replace mineral trioxide aggregate.

Biodentine™, defined as an active biosilicate, is bioactive and continues to produce hydroxyapatites long after blending. It can therefore fit the dentinal walls and improve its sealing capacity. BioRoot™ RCS -- a product obtained after testing these materials -- can ensure complete sealing of the root canal system after full cleaning and shaping. It is also an effective antibacterial agent.

Its biocompatibility has been recently evaluated in several studies, but there is no research published about the clinical effects of this material. It is a very interesting material because it perfectly adheres to both dentine and gutta percha, so that it can be used in cold sealing techniques.

This cannot be considered a monocone technology: in this technique, a single gutta percha cone is inserted into the canal -- which has [already] been filled with endodontic cement -- in an attempt to occupy the major part of the volume of the root canal. Since the endodontic cement is absorbable with time, this technology was [traditionally] considered highly ineffective, and not recommended by many practitioners. On the other hand, in cold sealing technology using bioceramics, the cement plays an important role because it is truly active in sealing the canal. The gutta percha cone -- which must be inserted quite deeply, near the apex -- is the only material which permits retreatments in the event of technical errors.

Conclusion

The case described above shows how it is possible to have excellent canal filling even in anatomically complex or compromised situations. Thanks to the excellent sealing capacity of bioceramics the periradicular tissues can recover

rapidly. Prospective clinical studies must in any case be conducted to evaluate the effectiveness of this technique, both in the medium and the long term.



Author:
Dr. Emanuele Ambu

1989, Graduated from Medicine and Surgery at the University of Bologna;
1998, Attend advanced post-graduate courses at the University of Florence.
2002-2003, Teaching of dental subjects at the University of Modena-Reggio Emilia
2005-2006, Coordinator of the Post-graduate Course in endodontics
2006-2008, obtain Master Degree in Endodontics at the University of Bologna
2011-2013, visiting professor at the Tuscan School of Medicine, University of Siena.
2013, visiting professor at the University of Cagliari.

Dr. Emanuele Ambu is currently (2016) a visiting professor in the teaching of “Retrograde Endodontics” at the Tuscan School of Medicine, University of Siena. He is also a visiting professor for the Master's Degree in Endodontics and the Master's Degree in Endodontics at the Universitat de Valencia.

Dr. Emanuele Ambu has published various articles on endodontic subjects for both Italian and international journals. He is a reviewer for the journal International Journal of Pediatric Dentistry, [as well as] for the journal Advances in Radiology and for the site Online Endo Academy. Speaker in courses and congresses in Italy and foreign countries since 1995. He works in his independent praxis in bologna as an endodontist and oral surgeon.

Download the complete series

Septodont Case Studies Collection

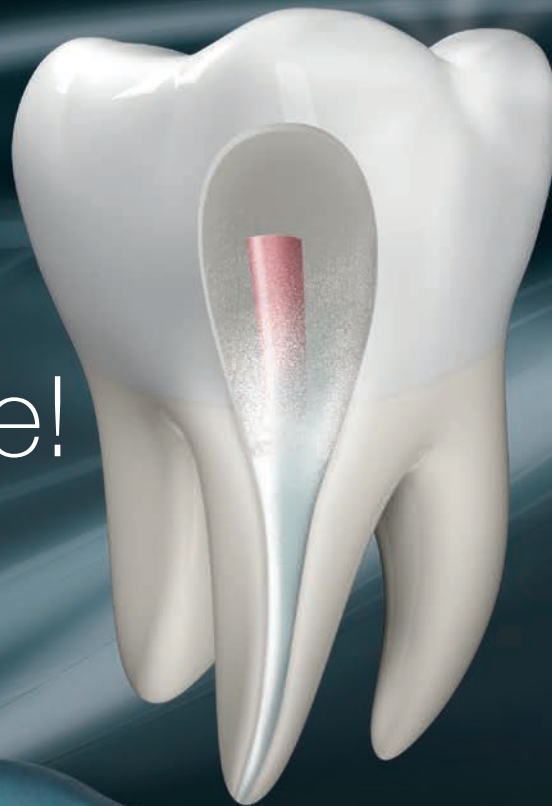
www.septodont.com



BioRoot™ RCS

No More
Compromise!

- Long term success
- Easy & fast technique



Endodontics

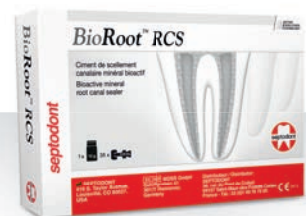For your endodontic obturations, BioRoot™ RCS offers you both an easy & fast technique along with long term clinical success. With BioRoot™ RCS, the clinical and procedural requirements that you face are fully met:

- Lateral & Apical long term seal
- Limit bacterial growth
- Easy and time effective to implement
- Cost effective

With BioRoot™ RCS, increase the standard of your endodontic obturation while optimizing your patients' chair time.

BioRoot™ RCS Succeed.

Please visit our website for more information
www.septodont.com



/// ACTIVE
BIOSILICATE
TECHNOLOGY





The Dental Pharmaceutical Company

INNOVATIVE, SAFE AND EFFECTIVE SOLUTIONS FOR DENTISTRY WORLDWIDE